



# ESTES recommendations on proximal humerus fractures in the elderly

Klaus W. Wendt<sup>1</sup> · Martin Jaeger<sup>2</sup> · Jan Verbruggen<sup>3</sup> · Stefaan Nijs<sup>4</sup> · Hans-Jörg Oestern<sup>5</sup> · Richard Kdolsky<sup>6</sup> · Radko Komadina<sup>7</sup>

Received: 22 August 2019 / Accepted: 12 July 2020 / Published online: 7 August 2020  
© Springer-Verlag GmbH Germany, part of Springer Nature 2020

## Abstract

**Purpose** The section for the skeletal trauma and sport's injuries of the European Society for Trauma and Emergency Surgery (ESTES) appointed a task force group to reach a consensus among European countries on proximal humeral fractures.

**Material/Methods** The task force group organized several consensus meetings until a paper with final recommendations was confirmed during the ESTES Executive Board meeting in Berlin on 25 October 2018.

**Conclusion** The Recommendations compare conservative and four possible operative treatment options (ORIF, nailing, hemi- and total reverse arthroplasty) and enable the smallest common denominator for the surgical treatment among ESTES members.

**Keywords** Proximal humeral fractures · Treatment options · Recommendations

## Abbreviations

AVM	Avascular necrosis
BMD	Bone mineral density
DEXA	Dual energy X-ray absorptiometry
HRMRI	High-resolution magnetic resonance imaging
ICF	International Classification of Functioning, Disability and Health
Micro-QCT	Micro-quantitative computed tomography
ORIF	Open reduction and internal fixation
PHN	Proximal humerus nail
ROM	Range of motion
RSA	Reverse shoulder arthroplasty

UBE	Upper body ergometer
WHO	World Health Organization

## Introduction

Proximal humeral fractures are among the most common fractures in the elderly [1]. Along with the increasing life expectancy of the Western population, the incidence of these fractures is rising rapidly, with osteoporosis as an important factor [2, 3]. Demographic research shows that proximal humeral fractures occur mostly in active persons aged 60 and older [4]. Around 90% of these patients live independently

✉ Radko Komadina  
radko.komadina@sb-celje.si

Klaus W. Wendt  
k.w.wendt@umcg.nl

Martin Jaeger  
martin.jaeger@uniklinik-freiburg.de

Jan Verbruggen  
j.verbruggen@mumc.nl

Stefaan Nijs  
Stefaan.Nijs@uzleuven.be

Hans-Jörg Oestern  
hans-joerg.oestern@t-online.de

Richard Kdolsky  
richard.kdolsky@meduniwien.ac.at

<sup>1</sup> Medical Coordinator, Trauma Centre Northern Netherlands, University Medical Center Groningen, Groningen, The Netherlands

<sup>2</sup> Clinic for Orthopedic and Trauma Surgery, Medical Center, Faculty of Medicine, University of Freiburg, Freiburg, Germany

<sup>3</sup> Department of Trauma Surgery, Maastricht University Medical Center, Maastricht, The Netherlands

<sup>4</sup> Department of Traumatology, UZ Leuven, Leuven, Belgium

<sup>5</sup> Conciliation Board of Medical Liability Cases Germany, Hannover, Germany

<sup>6</sup> University Clinic for Trauma Surgery, Medical University of Vienna, Vienna, Austria

<sup>7</sup> Medical Faculty, University of Ljubljana, Ljubljana, Slovenia

at home and do their own shopping and household chores. Hence, a proximal humeral fracture can potentially affect this independence and deteriorate the quality of life of the elderly.

Proximal humeral fractures can be identified as one-, two-, three- or four-part fractures according to the Neer classification, with three- and four-part fractures containing displaced fragments [5]. Treatment of minimally displaced or non-displaced fractures is mostly non-operative. For complex three- and four-part fractures, both operative and non-operative treatments are implemented in clinical practice [6–8]. Another, easier classification based on four main fragments was published by Hertel in 2004. Prognostic factors such as length of the medial metaphyseal head extension and integrity of the medial hinge are also very important [9] (Fig. 1).

Since the introduction of locking plates in the year 2000, operative treatment became a convenient option for elderly patients, as locking plates can also be used in osteoporotic bone [11, 12]. New nail designs were also introduced which achieve better stabilisation of the proximal fragments. Another option is joint replacement. Both hemiarthroplasty and total arthroplasty are performed. In recent decades reversed-type prostheses got a prominent place in the

treatment of proximal humerus fractures in the elderly, who are now treated operatively more than before the introduction of these techniques [8]. Operative treatment is nonetheless associated with a higher risk of complications related to the implant or the surgical procedure [13]. Current research has not been able to identify evident and reliable differences in outcome between operative and non-operative treatment [14, 15, 10]. This is supported by the latest Cochrane review [16].

Consensus is thus still lacking on the appropriate treatment for this type of fracture in elderly patients. Studies focus mainly on range of motion and functional and radiological outcomes [6, 10, 17], paying little attention to functioning in daily life and social participation even though these outcomes are of the utmost importance to patients. According to the International Classification of Functioning, Disability and Health (ICF) of the World Health Organization (WHO), assessment of health and disability includes the effect of trauma not only on the affected body function or structure but also the assessment of limitations in activity and restrictions in social participation [18]. Because of the lacking evidence, we cannot introduce recommendations as we did for hip fractures. In these recommendations, we will describe the different possibilities for treating proximal humerus fractures in the elderly, with all their advantages and disadvantages. We will also focus on the needs of this more frail group of patients. We will end by giving an overview about well-known necessary steps in the treatment of these fractures [19].

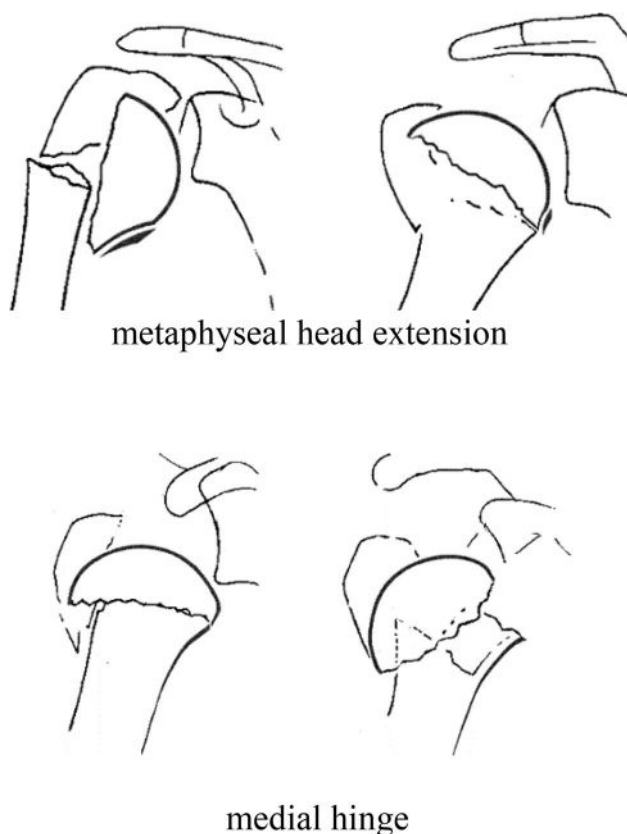


Fig. 1 prognostic factors for avascular head necrosis [10]

### Estes proximal humerus working group

Stefaan NijsBelgium.

Radko KomadinaSlovenia.

Martin JägerGermany.

Richard KdolskiAustria.

Hans Jörg OesternGermany.

Jan VerbruggenThe Netherlands.

Klaus Wendt The Netherlands.

### Patient group and aims

These recommendations focus on elderly people with a minor trauma of the proximal humerus. Minor trauma can be a fall in or outside the house from standing height. The main treatment goal is to restore the level of activity. This depends mainly on the demands of the patient. The goal necessitates a multidisciplinary approach. A trauma (orthopaedic) surgeon, anaesthesiologist, geriatrician, rehabilitation physician, general practitioner, emergency physician and physiotherapist can be part of the team. The coordinator

should be a trauma (orthopaedic) surgeon, who can monitor the whole process. This means that a care pathway for this patient group should be established.

## Clinical work-up

The work-up should include:

Anamnesis with the suspected information about low-energy trauma (fall from standing height onto the outstretched hand).

Information about previous injuries, surgeries, arthritis and osteoporosis is also needed. Pre-existing illnesses, allergies, medication (cortisol, cytostatics), hypocoagulation, nephropathy, diabetes, infections, neoplasms, metabolic bone disease (MPD), thyroid disease, obesity, hypogonadism are important issues.

Not every elderly patient is able to answer these questions adequately. Family, nursing home staff and paramedics are instrumental in this respect. Be aware of legal responsibilities and patient treatment limitations.

Thorough examination with inspection, palpation, possible demonstration of active moving of the upper extremity. Be aware of symptoms and signs such as painful restriction in range of motion, swelling, tenderness on palpation, haematoma, relieving posture (shoulder adduction and elbow flexion), crepitation, and local conditions of the axilla.

Exclusion of neurological and circulatory deficits distal to and on the site of the injured extremity.

After thorough analysis of the injury, we should proceed to diagnostic imaging:

- X-ray: AP view, axial view, Y view
- optional CT-scan (planning, injury of articular surface, dislocations, subluxations)
- MRI only for special problems (plexus injury, rotator cuff, pathological fracture)

Orthogeriatric examination, comorbidities, further pre-operative anaesthesiologic examination in case of operative indication: age, biological age, demands, social environment, mobility, propensity to fall, mental status, level of self-sufficiency, compliance, alcohol or drug abuse.

## Differential diagnosis

Glenohumeral dislocation.

AC dislocation.

Diaphyseal humerus fracture.

Rotator cuff rupture.

Scapular fracture.

## Classifications

Many classification systems are in use for proximal humerus fractures. They are all based on the basic principle of Codman published in 1934. The head and shaft fragment with the lesser and greater tubercle are the essential parts. Dislocation of these parts are caused by tendons which are attached to these structures. The subscapular muscle is attached to the lesser tubercle, the infra- and supraspinatus muscle are attached to the greater tubercle and the pectoralis muscle to the shaft (Fig. 2).

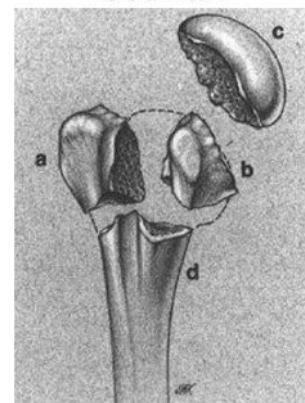
Neer published in 1970 his classification which is until today widely used. Fracture dislocation was defined as more than 1 cm or 45 grade. It is based on the X-ray before introduction of the CT scan. Many other authors have modified the Neer classification (Fig. 3).

The AO foundation first published in 1987 a comprehensive classification of long bones. After the first publication, it is many times modified and updated (Fig. 4). This classification is based on three niveaus:

- A extraarticular 2 part,
- B extraarticular 3 part,
- C intraarticular 4 part.

Hertel published in 2004 another very simple classification. It is a binary (LEGO) description system combining the five basic fracture planes and results in 12 basic fracture patterns. Basic fracture planes lie between the greater tuberosity and the head, the greater tuberosity and the shaft, the lesser tuberosity and the head, the lesser tuberosity and the shaft and between the lesser and greater tuberosity (Fig. 5).

Codman



**Fig. 2** Codman **a** Greater tubercle, **b** lesser tubercle, **c** head fragment, **d** shaft fragment [20]

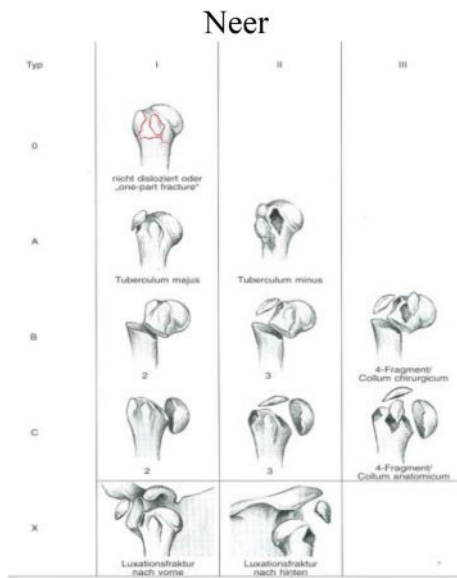


Fig. 3 Neer [21]

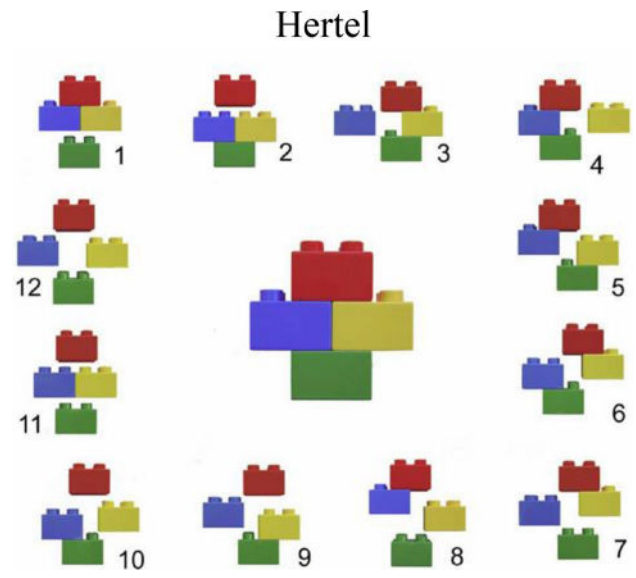


Fig. 5 Hertel [9]

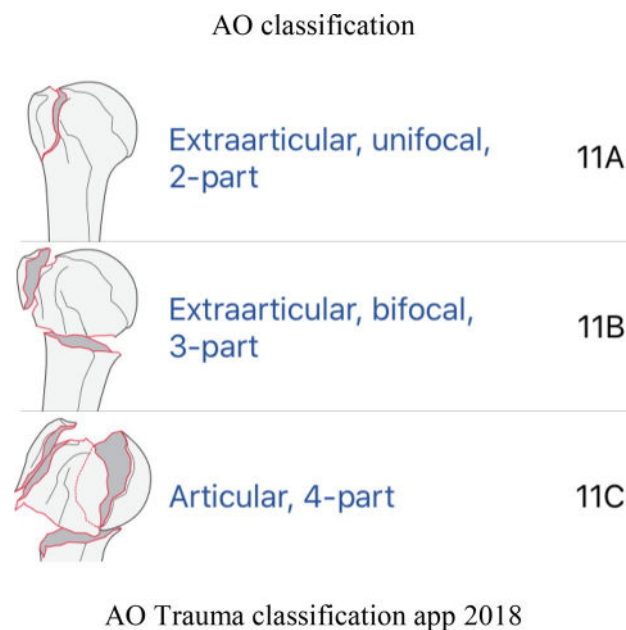

Fig. 4 AO Trauma classification app 2018 [22]

**Fracture biomechanics resulting from bone fragility**

Osteoporosis is a systemic skeletal disease with increased bone brittleness, which heightens the risk of fractures. Bone brittleness depends on bone density and quality [23]. Bone consists of organic collagen, which provides the bone with elasticity, and inorganic calcium hydroxyapatite, which gives the bone compressive strength. Both enable

bones to resist external forces and prevent deformity and fractures. A fracture is seen as a failure of both substance and structure [24]. An osteoporotic fracture is a result of both trauma and illness [25]. Hence, osteoporosis is the most common metabolic skeletal disease, as it affects bone substance and structure.

Recent discoveries are changing the outlook on osteoporosis diagnosis and treatment. DEXA-centric risk assessment has failed. Low bone mineral density (BMD) is a poor fracture-predicting factor, with an accuracy of only 50%; the rest is attributable to bone quality, which is not yet routinely measured (Micro-QCT and HR-MRI are possible methods). Bone strength depends on its mineral components, which are brittle yet highly resistant to compressive forces, and collagen, which gives elasticity. Only the mineral component can be measured with DEXA scanning. Both the mineral and the organic components are needed for the bone to resist external forces. Bone turnover, its microarchitecture and material properties (level of mineralisation, collagen denaturation, ability to quickly repair trabecular microfractures), all affect bone strength. The most important risk factors for an osteoporotic fracture are age, bone mineral density, low body mass index and prevalent fractures. Only low-impact forces, such as a fall from standing height, are needed for such a fracture [26]. Recurring falls from standing height are common among the geriatric population and are a part of frailty as a clinical syndrome. Frailty is also associated with sarcopenia, a loss of muscle volume and strength, both of which decrease with age. Limited mobility, recurring falls and earlier death are among its consequences.

The phenomenon of a fall with an osteoporotic fracture is explained by the Newitt model of bone frailty [27] as a

quotient between applied force as the numerator and bone strength as the denominator. Bone strength is the sum of bone quantity, measured with DEXA as BMD, and bone quality, which cannot be measured with DEXA (including properties such as elastic structure of bone tissue, collagen, microarchitecture of bone trabecules in the spongiosis which mitigate external forces in the epiphysis, thickness of cortical bone, and influence of bone shape and size at the impact location).

The dominant factor in a fracture is the patient falling. The coefficient of risk is the association between the external force acting on the bone and the force that actually causes the fracture (bone strength). We cannot differentiate the patients that are going to suffer a fracture in a population of patients of the same sex and with a low BMD. A frailty fracture is the result of both trauma (the numerator in the Newitt coefficient) and illness (the denominator).

The bone breaks when an external force causes it to deform. Studies on animal models and cadavers with a larger deformation (osteomalacia) and a smaller one (osteopetrosis) with the same BMD and microarchitecture of bone trabeculae do not give a definitive answer on risk fracture assessment. The term bone strength is more suitable and we obtain more information with histomorphometry, micro-QCT and HR-MRI than with DEXA alone. We can influence the Newitt numerator with fall prevention: raising muscle mass and physical mobility, and removing obstacles in the patient's environment, thus lowering the chances of falling. We can also influence the denominator: increasing BMD, physical activity, ensuring sufficient calcium and vitamin D intake, early detection of osteoporosis and long-term pharmacotherapy aimed at BMD loss prevention at an advanced age [25].

The stress/strain curve is used in a biomechanical analysis of increased bone brittleness along with the associations between bone size, shape and arrangement of mineral content in bone, and the properties of bone which are not seen with DEXA scanning. With these, we can try to explain osteoporotic fractures in elderly patients with a normal BMD on DEXA: intercortical porosity, increased bone remodeling, bone geometry, loss of mobility (via physical performance assessment) and osteosarcopenia. To that end, we need high-resolution radiographic methods such as a micro-QCT or HR-MRI. With a micro-QCT, we can measure the significant loss of trabecular bone without loss of cortical bone such as it occurs in early post-menopause.

WHO future projections show that the incidence of osteoporotic fractures will double or even triple in the next 30–50 years. Current pharmacological treatment is effective with the potential to cut the incidence of hip fractures and others by half. Due to the projected increase in fracture incidence, we need even more effective strategies to deal with geriatric skeletal trauma as an epidemic.

Pharmacological treatment, novel treatments aimed at molecular intracellular and intercellular pathways as well as strategies for preventing osteosarcopenia and maintaining mobility and reducing falling in the elderly will be needed.

## Conservative treatment

Prospective data on functional outcomes after conservative treatment are rare [28, 29, 30]. Court-Brown et al. [31] showed that in older patients, age, degree of dislocation and type of fracture are the main indicators of the functional outcome. Type of treatment (osteosynthesis vs conservative) did not have any influence on functional outcome. Gaebler [32] examined 507 non-dislocated or minimally dislocated fractures (< 1 cm < 45°) that were treated conservatively. In the follow-up, 1 year after the accident 87% of patients had good-to-excellent results. Patients under age 60 had a median Constant score of 80.7, those older than 60 a Constant score of 71. A great portion of the patients with modest or poor results had severe comorbidities, which are partly responsible for the diminished shoulder function [33].

## Classification issues

Proximal humeral fracture classifications may be helpful conceptually, but they have poor interobserver reliability even when utilising 3-D rather than 2-D CT. This may contribute to the similarly poor interobserver reliability that was observed when selecting treatment for proximal humeral fractures. The lack of a reliable classification confounds efforts to compare the outcomes of treatment methods among different clinical trials and reports.

## Indication and limitations of conservative treatment

In all age groups, there are fractures for which surgical treatment has clear benefits. Surgery may be necessary or recommended for:

- Dislocated fractures, in which the humeral head has dislocated from the shoulder socket.
- Open fractures, in which the bone penetrates the skin.
- Injuries to surrounding blood vessels and nerves.
- Humeral head split fractures, in which a portion of the humeral head breaks and disrupts the cartilage of the joint.
- Displaced fractures in younger patients.
- Fractures involving the attachments of the rotator cuff.



## Reduction

Conservative therapy is often misunderstood as doing nothing. Its influence in the sense of fragment manipulation is limited by the distal main fragment. Medial dislocations of the shaft > 50% primarily involve closed reduction performed under anaesthesia. With less medialisation, a small roll is placed in the armpit (axilla). In varus dislocation, an abduction splint can be used. Gravity is an essential element of treatment and can be strengthened by additional hand weights.

A problem of conservative treatment is the fact that the position of the short proximal main fragment is difficult to influence. One possibility is to manipulate the distal main fragment in the direction of the proximal main fragment. In dislocation of the head fragment in varus position, one should attempt to optimise the position by an abduction orthosis. Problems are compliance and wear comfort.

## Primary treatment and short description of the treatment periods

First, information of the patient about possible treatment options takes place.

Pain management: immobilisation of the shoulder with e.g. a Gilchrist bandage and pain medication.

The frequency of outpatient check-ups depends on pain, soft-tissue situation and comorbidities. The first radiological control should take place within one week to confirm the choice of treatment.

All pain-free and nearly painless exercises are allowed. The patient trains by himself.

After 3 weeks, the patient starts with pain-adapted pendulum exercises and guided movements up to 90°, and the Gilchrist is replaced by a shoulder bag if needed.

Pain-adapted exercises are done by the patient and supported by physiotherapy.

## Physiotherapy (under discussion)

### ROM

- Cervical, elbow and wrist ROM
- Pendulum exercises
- Instruct in home program

### Strengthening

- No cuff strengthening
- Begin and instruct in postural correction programme
- May begin scapular retraction and depression

- Grip strengthening

### Sling

- Arm in sling at all times except when exercising and bathing; includes sling at night (sleeping in recliner chair optimal); discontinue sling after 2–4 weeks

### Omit shoulder bag

Perform pain-adapted strengthening exercises (several times per day) supported by physiotherapy.

## Outpatient physiotherapy (weeks 5–8)

### ROM

- Begin self-assisted forward elevation to 90° and progress in 20° increments per week
- May use pulleys
- Begin self-assisted external rotation (ER) with progressive return to full ER in 20° increments per week
- Internal rotation (IR) in scapular plane as tolerated (no IR behind back)
- No cross-body adduction
- Grade I–II scapulothoracic and glenohumeral mobilisations

### Strength

- No cuff strengthening
- Continue scapular retraction and depression
- Lower extremity aerobic conditioning

### Other

- Modalities to decrease pain and inflammation
- Cryotherapy as necessary

## Outpatient physiotherapy phase (weeks 9–12)

### ROM

- Progressive return to full forward elevation and external rotation
- May begin posterior capsular stretching programme
- May begin IR behind back
- Grade III–IV glenohumeral and scapulothoracic mobilisations
- Begin anterior chest wall stretches (pectoralis minor)

## Strength

- Instruct in home programme and begin submaximal isometrics in flexion, abduction, IR, ER and extension
- Add progressive isotonic with low resistance, high repetitions as tolerated
- Emphasise anterior deltoid strength and scapular stabilisation
- Emphasise upper trapezius, serratus anterior force couple rehabilitation to create stable scapular base
- Assess and correct compensatory movement patterns
- UBE with low resistance
- Continue aerobic conditioning

## Outpatient physiotherapy (from week 12)

### ROM

- Progressive return to full motion in all planes
- Emphasise posterior capsule stretching
- Keep up home flexibility programme

### Strength

- Continue rotator cuff and scapular strengthening programme
- Progressive increase in resistance as strength improves
- Continue UBE with progressive resistance as tolerated
- Maintenance of aerobic conditioning home programme

Recreation-/vocation-specific rehabilitation.

## Plate osteosynthesis

The majority of proximal humerus fractures are not dislocated, and even dislocated fractures were the domain of conservative treatment before the introduction of angle-stable implants. As mentioned earlier, proximal humerus fractures are mainly the result of low-energy accidents such as a fall from standing height. Most patients are elderly, and osteoporosis is very common in this group. Standard implants like K-wires and plates did not provide enough stability in osteoporotic bone [34]. This often resulted in implant migration and secondary dislocation. After introduction of angle-stable implants the situation changed completely [35]. Angle-stable and anatomically pre-shaped plates have gained popularity [36, 37]. Their stability even in osteoporotic bone is excellent and secondary dislocation is the exception. Locking plates are generally mechanically superior to non-locking ones [38]. Much research has been conducted to choose the optimal size of the plate and number of screws. More screws, at

least 5, in the proximal fragment and the placement of an inferior medial support screw increase stability [39]. Another option to enhance stability is cement augmentation of the screws [40]. Medial support insertion, in the form of both screws and cement augmentation, generally improve mechanical stability [38]

The operation has to be performed in a supine or beach chair position on a radiolucent table. An image intensifier is necessary. There are two possible approaches: the deltopectoral approach and the less invasive deltoid split. There are no differences in clinical and radiological outcome between the two approaches, but the operation time is significantly shorter in the less invasive deltoid split approach [41–43]. It is important to achieve an anatomic reduction of the tubercula, therefore they have to be fixed by additional sutures. The combination of an angle-stable plate with additional sutures results in a high primary stability of the construct. Secondary dislocation is the exception. Even dislocated three- and four-fragment fractures in osteoporotic bone can be stabilised this way [38]. Augmentation of proximal head screws does not increase stiffness and failure loads but reduces motion at the bone-implant interface. The risk of secondary dislocation may be further reduced [41].

In 2009, Südkamp et al. published a study with initial results of 153 patients after a 1-year follow-up. The Constant score was 70.6 and the DASH score 15.2; 62 complications were seen in 52 patients (34%), and 21 patients (14%) had an unrecognised intraoperative screw perforation. To avoid this complication, a radiolucent operation table with an image intensifier is necessary. An option to avoid this complication is the use of polyaxial screws but the benefits remain unclear [38]. Another problem is subacromial impingement caused by a cranial position of the plate. A different plate design could solve this problem, but there is no certainty. Implant failure and postoperative cut-out is seen very rarely. Because of poor bone quality due to osteoporosis, distal bicortical fixation of the plate is necessary.

In a systematic review, in 12 studies, 282 patients aged 18 or older were identified with a Type C (AO classification) proximal humerus fracture. The Constant score was 53–75, revision surgery 6–44%, screw perforation 5–20% and subacromial impingement 7–11% [37]. Another systematic review with 514 patients out of 12 studies reported a Constant score of 74 and a DASH score of 27. The complication rate was 49% and without calling malunion a complication, it was still 33%. These studies included patients aged 18 and older and did not focus on elderly patients. A randomised controlled trial comparing 26 conservatively treated patients with 27 patients with open reduction and internal angle-stable plate fixation showed an advantage in functional outcome and quality of life for the locking plate but no significant difference between the two groups after a 2-year follow-up. The mean age was 74 years [44]:

	Conservative	Plate osteosynthesis	<i>p</i>
Constant score	58.4	61	0.64
DASH score	35	26.4	0.19
EQ-5D	0.59	0.70	0.26

Another prospective randomised trial with patients aged 60 and older and a B2 or C2 fracture according to the AO classification compared 23 plate osteosyntheses with conservative treatment. The 2-year follow-up showed no significant differences in the Constant score and the EQ-5D, but the EQ-5D favoured the operated group [45]. In both studies, every third patient out of the surgical group needed a reoperation.

In 2015, the results of the POFHER randomized clinical trial were published. It included 250 patients with a dislocated fracture involving the surgical neck. Mean age was 66 with a 24–92 range and a 2-year follow-up. This trial did not focus on the elderly. There were no significant differences in the Oxford Shoulder Score and the SF-12 score or complications requiring secondary surgery.

## Summary

Stable fixation of three- and four-part fractures can be achieved with an angle-stable plate even in osteoporotic bone. It is the main reason why this implant is used frequently in the treatment of proximal humerus fractures. The complication rate remains high and so far no advantage when comparing plate osteosynthesis with conservative treatment has been proven for the elderly, but powerful prospective research focusing on the elderly is still missing.

## Intramedullary locking nail

The first commercially available proximal humeral locking nail was the Polarus nail. The Constant Murley score (CM) was 88.4 points for 3-part and 67 points for 4-part fractures [46]. In a series of 20 patients, Agel et al. reported screw loosening in 15% of cases [47]. Functional results are satisfactory to excellent in 73.3–84% of cases in most papers [48–51]. Complication rates are rather high, with screw migration in 3–16% of cases and overall complications varying from 6 to as far as 70%. Bernard et al. and Nolan et al. reported 45 and 39% re-interventions, respectively [52, 53].

The T2® proximal humeral nail has a slightly bended design with four angular-stable locking screws proximally; two locking screws are used distally. Good healing results have been described; secondary dislocation with protruding nail are the primary complications [54, 55]. The introduction

site through the head fragment is recommended by von Ruden et al., because in this way, the head fragment is fixed on the nail, preventing secondary dislocation; this is also described by Stedtfeld et al. for the straight Targon nail [55, 56].

Popescou et al. reported good healing results in 21 patients. Mean CM was 65.7 points. Sosef et al. reported on a series of 33 elderly patients. Functional results were satisfactory to excellent according to the CM score, with a mean of 62 and the 4-part fractures scoring the lowest. Von Ruden et al. found a CM score of 72, and the elderly had significantly lower CM scores [55].

Several series on the Targon nail have been published [57–60]. Mittelmeier et al. reported good healing and functional results with a mean CM score of 78 points. Most important complications were 9 AVN, 3 infections and 26 screw dislocations. Gradl et al. also found mainly AVN and secondary screw dislocation as complications, reporting a mean CM of 79 points after one year. Matthews had comparable results [57–59].

The PHN by Synthes is a short nail with a twisted blade fixating the humeral head. Blum et al. reported good results with a CM score of 75.3. Most important complications were perforation of the head fragment and implant-related pain. Due to the design of the implant, multifragment fractures cannot be stabilized with it [60]. In another study on 22, 2-part proximal humeral fractures, Zhu et al. mentioned a CM of 85.4 and no implant-related complications [61].

The Multiloc nail has several locking options in the humeral head. An extra feature is the screws in screw-locking bolts. One publication with preliminary results reported a CM score of 66.1 [62]. Hao and Wee published a series of 22 patients that had good functional results, with a CM of 75.5 and a correlation between CM and fracture type [63].

The Telegraph nail is a straight nail. There are only a few publications on it [64–66]. Cuny et al. reported on a total of 67 patients. Functional results were satisfactory, with a CM score of 62 points and 60 points for individuals older than 70. Complication rates were high, with implant removal in 31% of cases [64]. Boughebri reported a CM score of 62 points [66]. Other nail types have been reported with comparable results [67–69].

## Biomechanics

After the introduction of proximal humeral nails, several studies on the biomechanics of these implants have been published. Biomechanical studies mostly compared the nails with plate osteosynthesis. Different measuring methods and units have been used to quantify stiffness and stability. Most models were two-part fractures with a cortical defect to mimic an unstable fracture pattern. In some studies, a three-part model is used.



Hessmann compared the classical T-plate with the experimental Philos plate and the Proximal Humeral Nail by Synthes. In axial stability, the PHN was more stable than the other implants, but not in torsion. Also in case of destructive loading, the nail was stiffer than the plates [70].

Fuchtmeier et al. compared the Sirius nail with the PHN (Synthes) and the plate. The nail constructs were significantly stiffer than the plate [71, 72]. Kitson et al. compared a proximal humeral nail with a proximal humeral plate. Both in bending and in torsion, the nail was stiffer than the plate. Only in varus bending were there no significant differences [73]. Rothstock et al. compared two straight nailing systems, the Multiloc and the Targon PH. Though the multilock with screw in screw fixation and a calcar screw appeared to be more stable, there were no significant differences in bending or in torsion stiffness. Yoon et al. compared locking plates and conventional plates with intramedullary nails with and without angular-stable locking screws. All the nail constructs were significantly stiffer than the plate constructs [74]. Clavert et al. came to the same conclusion [75]. Furoria et al. found no difference in bending stiffness, but locking plates did have a higher torsional stiffness [76]. Only one publication concluded that plates were more stable than nails in bending and torsion [77].

From these biomechanical studies, one may conclude that intramedullary implants in the treatment of proximal humeral fractures create more stability than plates. Recently developed locking plates are more stable than older conventional plates. This may be of interest in case of osteoporotic bone.

## Evidence

No prospective randomised studies comparing nails and plates have been published. Most evidence is based on meta-analyses or retrospective comparative studies. It can generally be concluded that there is no evidence for the superiority of either technique. Functional results appear to be determined by fracture complexity and patient age.

Lange et al. compared a prospective series of IM nailing with a retrospective group of non-operatively treated patients in a matched pair analysis, and could not find any statistically significant differences in function between the two groups. Non-operative treatment did lead to fewer complications [78]. Von Ruden et al. did not find significant differences in function between nail and plate after 3 years, and concluded that an intramedullary implant has biomechanical advantages and leads to less soft-tissue damage [55]. Gradl et al. could not find any significant differences between plates or nails either [79].

Boudard et al. compared plating and nailing in four-part fractures in a prospective cohort study. They found no significant differences between the two techniques, except for

screw migration in the nail. In the group treated with nailing, however, three different nails had been used [80]. In a prospective comparative cohort study of three-part proximal humeral fractures, Konrad et al. compared the plate and the PHN. There were no significant differences between the two techniques in terms of function and healing. The patients in the nailing group did have significantly less pain [81].

In a retrospective study, Lekic et al. compared the T2 proximal humeral nail with the locking plate and could not find significant differences between the two groups on function and complications [82]. In a randomised trial, Lopiz et al. compared the straight Multiloc nail with the bended Polarus nail. The Polarus nail had significantly more symptoms related with rotator cuff disease. Reoperation rate was 42% for the Polarus and 11.5% for the Multiloc. Healing results were comparable [83]. In a meta-analysis of 615 patients comparing nails with plates, Wang et al. could not find evidence for either technique. Functional results and complications were comparable for both implants [84].

## Summary

Based on the current literature, there is no evidence for either treatment of proximal humeral fractures. In general, the nail is a proper implant for the treatment of different types of proximal humeral fractures. It has some advantages because of its minimally invasive technique: less soft-tissue damage and shorter operation time. Several tests show the biomechanical superiority of the intramedullary nail. This can be advantageous for elderly osteoporotic patients. Functional results seem to be determined mainly by fracture type and patient age. Based on the literature, one could recommend the use of a proximal humeral nail to treat proximal humeral fractures.

## Prosthesis inclusive reversed type

The outcome of proximal humerus fractures depends on the shape, stability and vascularity of the proximal humerus [27]. The possibilities to influence the shape of displaced proximal humerus fractures conservatively are limited, therefore, in many cases, the outcome is compromised by the impaired shape. In terms of construction, surgical treatment tries to restore and preserve the shape as well as possible. Unfortunately, we still fail frequently, requiring revision surgery in up to 13% of cases [85].

Current problems/challenges in the treatment of proximal humerus fractures are:

- Poor bone quality
- Displaced, multifragmentary fractures of the tuberosities
- 4-part fracture dislocations

- 4-part fractures with a displaced, very thin humeral head segment
- Varus displaced fractures
- Head split fractures
- Fractures with high risk of ischemia according to Hertel's criteria

These fractures do not do well after non-operative treatment. They also have a high likelihood to fail after open reconstruction and internal fixation. Under those conditions, a shoulder replacement might be indicated.

## Hemiarthroplasty

For decades, a stemmed shoulder hemiarthroplasty has been a treatment option for severely comminuted and displaced fractures of the proximal humerus. Although the clinical outcome was supposed to be superior compared to non-operative treatment or open reduction and internal fixation, recent evidence is still lacking that demonstrates the superiority of hemiarthroplasty. Three prospective randomised trials have been published so far, comparing hemiarthroplasty to non-operative treatment [86–88]. They all demonstrate at least comparable outcomes after non-operative treatment. The outcome of hemiarthroplasty depends strongly on the proper indication, correct implantation of the prosthesis and the anatomic ingrowth of the tuberosities [89–91]. If the osteosynthesis of the tuberosities fails, a poor outcome can be expected due to an insufficiency of the rotator cuff and an ensuing joint instability. Besides that, the main complications reported include aseptic loosening, dislocation and infection.

In a meta-analysis reviewing the outcome of shoulder hemiarthroplasty after acute proximal humerus fractures Nijs states frustrating results [92]. Tuberosity healing influenced the functional outcome in all studies and showed a negative correlation between increasing age and functional outcome. Kontakis conducted a systematic review including 16 studies with 810 hemiarthroplasties for acute proximal humerus fractures [93]. The mean Constant score was 56 (11–98), and high complication rates were reported. Tuberosity-related complications were observed in 11% of cases and a proximal migration of the humeral head was subsequently seen in 6.8% of cases.

Borowsky highlights that the suture repair of the tuberosities results in mechanical weaknesses and that the failure is related to a mechanical phenomenon [94]. Movements of at least 1 cm were observed in almost every mechanical testing after 8000 cycles. All sutures became loose, dug into the tendons and cut through the bone. Collapse of the cancellous bony volume was identified as the reason for looseness and migration of the sutures. Lambert also stresses the importance of vascularity [95]. The integrity of the periosteum is

a crucial factor for keeping the tuberosities alive, therefore, periosteal preservation during fixation of the tuberosities is mandatory.

Factors that challenge the fixation and healing of the tuberosities after hemiarthroplasty for proximal humerus fractures involve:

- multifragmentary tuberosities
- avulsion-type tuberosity fractures, like those seen in fracture dislocations
- poor bone quality

## Reverse shoulder arthroplasty

In recent years, reverse shoulder arthroplasty has gained popularity in the treatment of proximal humerus fractures, especially in the elderly population. The main reason for this phenomenon is that the outcome seems to be much more predictable, compared to hemiarthroplasty, because it does not depend on the ingrowth of the tuberosities to such an extent. The overall revision surgery rate drops to 5% compared to 12.7% after ORIF [85]. Cuff reports on the outcome of a prospective cohort study including 53 patients with proximal humerus fractures treated with either hemiarthroplasty or reverse shoulder arthroplasty [96]. Functional outcome and patient-reported satisfaction scores were lower after hemiarthroplasty [97–104]. Radiographic healing of the tuberosities occurred in 61% of the patients in the hemiarthroplasty group compared with 83% of the patients in the RSA group. Forward elevation of the arm was higher in the RSA group (139°) than in the HA group (100°) ( $p=0.0002$ ). There were no significant differences for internal and external rotation. The functional outcome in the presence of non-healed tuberosities was much better for reverse shoulder arthroplasty. Complication rates in both groups were similar. Sebastián-Forcada confirms these results in a prospective randomised study comparing reverse shoulder arthroplasty with hemiarthroplasty for acute proximal humerus fractures that enrolled 62 patients older than 70 [105]. Reverse shoulder arthroplasty resulted in significantly better pain and function rates and a lower revision rate. The mean Constant score after hemiarthroplasty was 40 (8–74), compared to 56 (24–80) after reverse shoulder arthroplasty. For reverse shoulder arthroplasty, the functional outcome did not depend on the healing of the tuberosities. There were no significant differences between failure and healing subgroups on mean Constant score. In contrast, patients with failure of the tuberosities after hemiarthroplasty had significantly worse functional outcomes.

It seems important to mention that the Kaplan–Meier arthroplasty survival curves with revision or clinical failure as end point demonstrate 71% survival 40 months after surgery after reverse shoulder arthroplasty and only 43.3% after

hemiarthroplasty. The New Zealand Joint Registry demonstrates almost comparable Oxford Scores after six months for both hemiarthroplasty and reverse shoulder arthroplasty [106]. After 5 years, the Oxford Scores were significantly better following reverse shoulder arthroplasty (41.5 vs 32.3). A Nordic registry-based study on 6756 cases demonstrates rare revisions after shoulder arthroplasty for fractures [107]. The cumulative survival rate was 0.96 for both hemiarthroplasty and reverse shoulder arthroplasty after 5 years. Reverse shoulder arthroplasty had a significantly higher and clinically relevant risk of revision because of infection.

These results were encouraging. Especially, elderly patients requiring a surgical approach for proximal humerus fractures appreciate a procedure with high predictability in terms of pain relief and restoration of function necessary for daily activities, which can be offered by reverse shoulder arthroplasty. It is the only treatment option that seems not to rely on the healing of the tuberosities.

Since the outcome after reverse shoulder arthroplasty is still good in many cases even when the tuberosities are not healed, it is a matter of debate whether the tuberosities should be fixed after this procedure at all. Fixation of the tuberosities seems to result in a better functional outcome, especially in terms of rotation and a lower dislocation rate. But it requires a more prolonged rehabilitation using a shoulder abduction pillow for several weeks, compared to a quicker rehabilitation if the tuberosities were not fixed. That might be important, as elderly patients frequently use a walker, which cannot be used with a shoulder abduction pillow. In addition, they would be more dependent on others' help, losing their self-reliance for several weeks.

Another open question is the type of reverse shoulder arthroplasty. In contrast to the classic Grammont design, recent prostheses offer an inclination of 145° or even 135°, which lowers the amount of humeral distalisation. This might be beneficial. The lateralisation yields better function of the rotators if the tuberosities are fixed. In addition, the notching is lowered, which seems to be advantageous for the deltoid muscle, as it should not be overtensioned in the long term. Fatigue of the deltoid muscle remains still remains a problem after several years.

### Platform systems

Recent fracture prostheses include what are known as platform systems. These types of prostheses allow conversion of a failed anatomic hemiarthroplasty into a reverse shoulder

arthroplasty without removal of the stem. The stem serves as a platform for both the anatomic prosthetic head and the reverse metaphysis. This type of prosthesis seems to be promising, since stem removal-related complications can be avoided if a conversion is intended. Whether this kind of prosthesis will be accepted is not clear at the moment. If the tuberosities do not heal because of the above-mentioned reasons, the failure will become symptomatic within the first postoperative year. If the conversion into a reverse shoulder arthroplasty becomes necessary within this short period of time, the patient will ask why the reverse shoulder arthroplasty was not performed right away, independently of his age but especially if he is older than 75. Additionally, converting into a reverse shoulder arthroplasty with retention of the humeral component can lengthen the arm significantly, up to 4.7 cm (mean 2.6 cm) [108]. That puts the neurological structures and the deltoid muscle at risk over time. Malpositioned stems, which are implanted too high in a valgus position or a malrotation, require a stem removal regardless of their design.

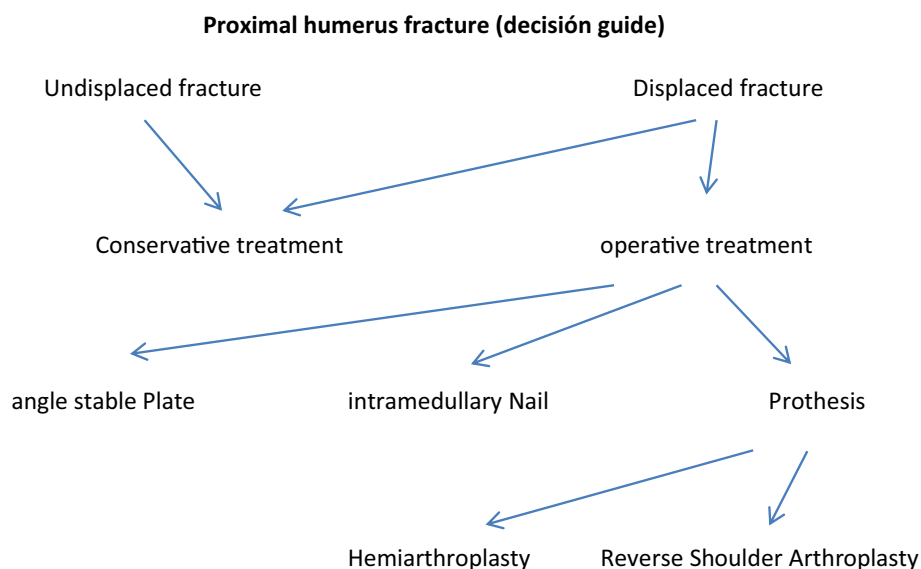
### Summary

Evidence-based recommendations are still lacking. In selected patients, shoulder replacement is a reliable treatment option for proximal humerus fractures. The use of hemiarthroplasty is still appropriate if fixation and healing of the tuberosities seem achievable. Unfortunately, this is in the majority of the fractures not the case. Patients' age, gender, presence of comminuted tuberosities, avulsion-type fractures and poor bone quality are risk factors for failure. There is a strong trend towards reverse shoulder arthroplasty, especially in patients older than 75. Reverse shoulder arthroplasty can provide good clinical outcome with a low number of revisions.

### Considerations

As mentioned before, evidence and consensus about the treatment of proximal humerus fractures is still missing. In these recommendations, we give an overview about possible treatment strategies with their advantages, disadvantages and the state of the current literature. Further research about this very important injury is absolute necessary (Fig. 6).

**Fig. 6** Proximal humerus fracture (decisión guide)



## Compliance with ethical standards

**Conflict of interest** The authors have no conflicts of interest to report.

## References

- Barrett JA, Baron JA, Karagas MR, Beach ML. Fracture risk in the US medicare population. *J Clin Epidemiol*. 1999;52(3):243–9.
- Palvanen M, Kannus P, Niemi S, Parkkari J. Update in the epidemiology of proximal humeral fractures. *Clin Orthop Relat Res*. 2006;442:87–92.
- Johnell O, Kanis J. Epidemiology of osteoporotic fractures. *Osteoporos Int*. 2005;16(2):S3–S7.
- Court-Brown CM, Caesar B. Epidemiology of adult fractures: a review. *Injury*. 2006;37(8):691–7.
- Neer CS. Displaced proximal humeral fractures: part I. Classification and evaluation. *J Bone Joint Surg Am*. 1970;52(6):1077–89.
- Hanson B, Neidenbach P, de Boer P, Stengel D. Functional outcomes after nonoperative management of fractures of the proximal humerus. *J Shoulder Elbow Surg*. 2009;18(4):612–21.
- Zyto K. Non-operative treatment of comminuted fractures of the proximal humerus in elderly patients. *Injury*. 1998;29(5):349–52.
- Bell JE, Leung BC, Spratt KF, Koval KJ, Weinstein JD, Goodman DC, et al. Trends and variation in incidence, surgical treatment, and repeat surgery of proximal humeral fractures in the elderly. *J Bone Joint Surg Am*. 2011;93(2):121–31.
- Hertel R, Hempfing A, Stiehler M, Leunig M. Predictors of humeral head ischemia after intracapsular fracture of the proximal humerus. *J Shoulder Elbow Surg*. 2004;13(4):427–33.
- Fjalestad T, Hole MO, Hovden IA, Blucher J, Stromsoe K. Surgical treatment with an angular stable plate for complex displaced proximal humeral fractures in elderly patients: a randomized controlled trial. *J Orthop Trauma*. 2012;26(2):98–106.
- Miranda MA. Locking plate technology and its role in osteoporotic fractures. *Injury*. 2007;38(3):S35–S39.
- Roderer G, Gebhard F, Krischak G, Wilke HJ, Claes L. Biomechanical in vitro assessment of fixed angle plating using a new concept of locking for the treatment of osteoporotic proximal humerus fractures. *Int Orthop*. 2011;35(4):535–41.
- Clavert P, Adam P, Bevort A, Bonnomet F, Kempf JF. Pitfalls and complications with locking plate for proximal humerus fracture. *J Shoulder Elbow Surg*. 2010;19(4):489–94.
- Olerud P, Ahrengart L, Ponzer S, Saving J, Tidermark J. Internal fixation versus nonoperative treatment of displaced 3-part proximal humeral fractures in elderly patients: a randomized controlled trial. *J Shoulder Elbow Surg*. 2011;20(5):747–55.
- Sanders RJ, Thissen LG, Teepen JC, van Kampen A, Jaarsma RL. Locking plate versus nonsurgical treatment for proximal humeral fractures: better midterm outcome with nonsurgical treatment. *J Shoulder Elbow Surg*. 2011;20(7):1118–24.
- Handoll HH, Brorson S. Interventions for treating proximal humeral fractures in adults. *Cochrane Database Syst Rev*. 2015;11:CD000434.
- Zyto K, Ahrengart L, Sperber A, Tornkvist H. Treatment of displaced proximal humeral fractures in elderly patients. *J Bone Joint Surg Br*. 1997;79(3):412–7.
- World Health Organization. International classification of functioning, disability and health (ICF). Geneva: World Health Organization; 2001.
- Hirzinger C, Tauber M, Resch H. Proximal humerus fracture: new aspects in epidemiology, fracture morphology, and diagnostics. *Unfallchirurg*. 2011;114:1051–8.
- Codman E. Fractures in relation to the subacromial bursa. In: Codman E, editor. *The shoulder: rupture of the supraspinatus tendon and other lesions about the subacromial bursa*. Boston: Thomas Todd Company; 1943.
- Neer CS II. Displaced Proximal Humerus Fractures: Part I: Classification and Evaluation. *J Bone Joint Surg [A]*. 1970;52:1077–89.
- Müller ME, Nazarian S, Koch P. *Classification AO des fractures*. Berlin: Springer Verlag; 1987.
- Seeman E, Delmas PD. Bone quality—the material and structural basis of bone strength and fragility. *N Engl J Med*. 2006;354:2250–61.
- Paci M, Burks S, Wang MY. Consensus guidelines for the treatment of osteoporosis. *Neurosurgery*. 2018;82(1):N6–7.
- Komadina R. Hip, osteoporosis, new paradigm. *Eur J Trauma Emerg Surg*. 2008;2:163–70.



26. Cummings SR, Newitt MC. A hypothesis: the causes of hip fracture. *J Gerontol.* 1989;44:107–11.
27. Boons HW, Goosen JH, van Grinsven S, von Susante JL, van Loon CJ. Hemiarthroplasty for humeral four-part fractures for patients 65 years and older: a randomized controlled trial. *Clin Orthop Relat Res.* 2012;470:3483–91.
28. Brouwer ME, Reininga IHF, El Moumni M, Wendt KW. Outcomes of operative and nonoperative treatment of 3- and 4-part proximal humeral fractures in elderly: a 10-year retrospective cohort study. *Eur J Trauma Emerg Surg.* 2019;45:131–8.
29. Fjalestad T, Hole MO, Jorgensen JJ, Stromsoe K, Kristiansen IS. Health and cost consequences of surgical versus conservative treatment for a comminuted proximal humeral fracture in elderly patients. *Injury.* 2010;41:599–605.
30. Fjalestad T, Hole MO. Displaced proximal humeral fractures: operative versus non-operative treatment. *Eur J Orthop Surg Traumatol.* 2014;24(7):1067–73.
31. Court-Brown CM, Garg A, McQueen MM. The translated two-part fracture of the proximal humerus—epidemiology and outcome in the older patient. *J Bone Joint Surg Br.* 2002;84:504–8.
32. Gaebler C, McQueen MM, Court-Brown CM. Minimally displaced proximal humeral fractures: epidemiology and outcome in 507 cases. *Acta Orthop Scand.* 2003;74:580–5.
33. Olerod P, Ahrengart L, Ponzer S, Saving J, Tidermark J. Internal fixation versus nonoperative treatment of displaced 3-part proximal humeral fractures in elderly patients: a randomized controlled trial. *J Shoulder Elbow Surg.* 2011;20:747–55.
34. Resch H, Povacz P, Frohlich R, Wambacher M. Percutaneous fixation of three- and four-part fractures of the proximal humerus. *J Bone Joint Surg [Br].* 1997;79:295–300.
35. Fjalestad T, Hole MØ, Hovden IA, Blücher J, Strømsøe K. Surgical treatment with an angular stable plate for complex displaced proximal humeral fractures in elderly patients: a randomized controlled trial. *J Orthop Trauma.* 2012;26:98–106.
36. Südkamp N, Baver J, Hepp P, et al. Open reduction en internal fixation of proximal humerus fractures with the use of LPHP. *J Bone Joint AM.* 2009;91(6):1320–8.
37. Brorson S, Rasmussen JV, Frich LH, et al. Benefits and harms of locking plate osteosynthesis in intraarticular (OTA Type C) fractures of the proximal humerus: a systematic review. *Injury.* 2012;43:999–1005.
38. Rangan A, Handoll H, Brealey S, et al. Surgical versus non-surgical treatment of adults with displaced fractures of the proximal humerus. *PROFHER Randomized Trial JAMA.* 2015;313(10):1037–47. <https://doi.org/10.1001/jama.2015.1629>.
39. Erhardt JB, Stoffel K, Kampshoff J, et al. The position and number of screws influence screw perforation of the humeral head in modern locking plates: a cadaver study. *J Orthop Trauma.* 2012;26(10):188–92.
40. Schliemann B, Waehnert D, Theisen C, et al. How to enhance the stability of locking plate fixation of proximal humerus fractures? An overview of current biomechanical data. *Injury.* 2015;46(7):1207–14.
41. Schliemann B, Seifert R, Rossienbroich SB et al. Screw augmentation reduces motion at the bone-implant interface: a biomechanical study of locking plate fixation of proximal humeral fractures. *J Shoulder Elbow Surg* 2015;24(12):1968–73.
42. Ruchholtz S, Hauk C, Lewan U, et al. Minimal invasive Polyaxial Locking plate fixation in proximal humerus fractures: a prospective study. *J Trauma.* 2011;71(6):1737–44.
43. Jabran A, Peach C, Ren L. Biomechanical analysis of plate systems for proximal humerus fractures: a systematic literature review. *Biomed Eng Online.* 2018;17:47.
44. Sproul RC, Iyengar JJ, Devcic Z, et al. A systematic review of locking plate fixation of prox. Humerus fractures *Injury.* 2011;42(4):408–13.
45. Olerud P, Ahrengart L, Ponzer S, et al. Internal fixation versus nonoperative treatment of displaced 3-part prox. Humeral fractures in elderly: a randomized controlled trial. *J Shoulder Elbow Surg.* 2011;20(5):747–55.
46. Sohn HS, Jeon YS, Lee J, et al. Clinical comparison between open plating and minimally invasive plate osteosynthesis for displaced proximal humeral fractures: a prospective randomized controlled trial. *Injury.* 2017;48(6):1175–82.
47. Adedapo AO, Ikpeme JO. The results of internal fixation of three- and four-part proximal humeral fractures with the Polarus nail. *Injury.* 2001;32(2):115–21.
48. Agel J, Jones CB, Sanzone AG, et al. Treatment of proximal humeral fractures with Polarus nail fixation. *J Shoulder Elbow Surg.* 2004;13(2):191–5.
49. Dall'Oca C, Maluta T, Leone N, et al. The treatment of proximal humeral fractures with a "Polarus" intramedullary nail. *Acta Biomed.* 2014;85(2):25–30.
50. Georgousis M, Kontogeorgakos V, Kourkouvelas S, et al. Internal fixation of proximal humerus fractures with the polarus intramedullary nail. *Acta Orthop Belg.* 2010;76(4):462–7.
51. Rajasekhar C, Ray PS, Bhamra MS. Fixation of proximal humeral fractures with the Polarus nail. *J Shoulder Elbow Surg.* 2001;10(1):7–10.
52. Giannoudis PV, Xypnitos FN, Dimitriou R, et al. Internal fixation of proximal humeral fractures using the Polarus intramedullary nail: our institutional experience and review of the literature. *J Orthop Surg Res.* 2012;7:39. <https://doi.org/10.1186/1749-799X-7-39>.
53. Bernard J, Charalambides C, Aderinto J, et al. Early failure of intramedullary nailing for proximal humeral fractures. *Injury.* 2000;31(10):789–92.
54. Nolan BM, Kippe MA, Waiter JM, et al. Surgical treatment of displaced proximal humerus fractures with a short intramedullary nail. *J Shoulder Elbow Surg.* 2011;20(8):1241–7.
55. Sosef N, van Leerdam R, Ott P, et al. Minimal invasive fixation of proximal humeral; fractures with an intramedullary nail: good results in elderly patients. *Arch Orthop Trauma Surg.* 2010;130(5):605–11.
56. von Rueden C, Trapp O, Hierholzer C, et al. Intramedullary nailing vs. locking plate osteosynthesis in proximal humeral fractures: long-term outcome. *Unfallchirurg.* 2015;118(8):686–92.
57. Stedtfeld HW, Mittlmeier T. Fixation of proximal humeral fractures with an intramedullary nail: tips and tricks. *Eur J Trauma Emerg Surg.* 2007;33(4):367–74.
58. Mittlmeier TW, Stedtfeld HW, Ewert A, et al. Stabilization of proximal humeral fractures with an angular and sliding stable antegrade locking nail (Targon PH). *J Bone Joint Surg Am.* 2003;85-A(4):136–46.
59. Gradl G, Dietze A, Arndt D, et al. Angular and sliding stable antegrade nailing (Targon PH) for the treatment of proximal humeral fractures. *Arch Orthop Trauma Surg.* 2007;127(10):937–44.
60. Mathews J, Lobenhoffer P. The Targon PH nail as an internal fixator for unstable fractures of the proximal humerus. *Oper Orthop Traumatol.* 2007;19(3):255–75.
61. Blum J, Hansen M, Rommens RM. Angle-stable intramedullary nailing of proximal humerus fractures with the PHN (proximal humeral nail). *Oper Orthop Traumatol.* 2009;21(3):296–311.
62. Zhu Y, Lu Y, Wang M, et al. Treatment of proximal humeral fracture with a proximal humeral nail. *J Shoulder Elbow Surg.* 2010;19(2):297–302. <https://doi.org/10.1016/j.jse.2009.05.013>.
63. Hessmann MH, Nijs S, Mittlmeier T, et al. Internal fixation of fractures of the proximal humerus with the MultiLoc nail. *Oper Orthop Traumatol.* 2012;24(4–5):418–31. <https://doi.org/10.1007/s00064-011-0085-z>.



64. Hao TD, Huat AWT. Surgical technique and early outcomes of intramedullary nailing of displaced proximal humeral fractures in an Asian population using a contemporary straight nail design. *J Orthop Surg (Hong Kong)*. 2017;25(2):2309499017713934.
65. Cuny C, Pfeffer F, Irrazi M, Chammas M, Empereur F, Berrichi A, Metais P, Beau P. Un nouveau clou verrouillé pour les fractures proximales de l'humérus [A new locking nail for proximal humerus fractures: the Telegraph nail, technique and preliminary results]. *Rev Chir Orthop Reparatrice Appar Mot*. 2002;88:62–7.
66. Garret J, Houdré H, Cieviet-Bonfils M, et al. Surgical treatment of complex proximal humeral fractures with a technique of nail and osteosuture: "NOS". *Eur J Orthop Surg Traumatol*. 2017;27(3):391–7.
67. Boughebi O, Havet E, Sanguina M, et al. Treatment of proximal humeral fractures by Telegraph nail: prospective study of 34 cases. *Rev Chir Orthop Reparatrice Appar Mot*. 2007;93(4):325–32.
68. Liu QH, Sun W, Zhou JL, et al. A new approach for the treatment of proximal humeral fractures using the TRIGEN proximal humeral nail. *Eur J Orthop Surg Traumatol*. 2014;24(4):467–74.
69. Fuechtmeier B, Broeckner S, Hente R, et al. The treatment of dislocated humeral head fractures with a new proximal intramedullary nail system. *Int Orthop*. 2008;32(6):759–65.
70. Freynik F, Freynik S, Zenker W, et al. Angular and sliding stable internal fixation of proximal humerus fractures using the "Varion" intramedullary nail. *Z Orthop Unfall*. 2013;151(4):343–9.
71. Hessmann MH, Hansen WS, Kruppenauer F, et al. Locked plate fixation and intramedullary nailing for proximal humerus fractures: a biomechanical evaluation. *J Trauma*. 2005;58(6):1194–201.
72. Füchtmeier B, May R, Fierlbeck J, Hammer J, Nerlich M. A comparative biomechanical analysis of implants for the stabilization of proximal humerus fractures. *Technol Health Care*. 2006;14:261–70.
73. Fuechtmeier B, May R, Hente R, et al. Proximal humerus fractures: a comparative biomechanical analysis of intra and extramedullary implants. *Arch Orthop Trauma Surg*. 2007;127(6):441–7.
74. Kitson J, Booth G, Day R. A biomechanical comparison of locking plate and locking nail implants used for fractures of the proximal humerus. *J Shoulder Elbow Surg*. 2007;16(3):362–6.
75. Yoon RS, Dziadosz D, Porter DA, et al. A comprehensive update on current fixation options for two-part proximal humerus fractures: a biomechanical investigation. *Injury*. 2014;45(3):510–4.
76. Clavert P, Hatzidakis A, Boileau P. Anatomical and biomechanical evaluation of an intramedullary nail for fractures of proximal humerus fractures based on tuberosity fixation. *Clin Biomech (Bristol, Avon)*. 2016;32:108–12.
77. Foruria AM, Carrascal MT, Revilla C, et al. Proximal humerus fracture rotational stability after fixation using a locking plate or a fixed-angle locked nail: the role of implant stiffness. *Clin Biomech (Bristol, Avon)*. 2010;25(4):307–11.
78. Edwards SL, Wilson NA, Zhang LQ, et al. Two-part surgical neck fractures of the proximal part of the humerus. A biomechanical evaluation of two fixation techniques. *J Bone Joint Surg Am*. 2006;88(10):2258–64.
79. Lange M, Brandt D, Mittlmeier T, et al. Proximal humeral fractures: non-operative treatment versus intramedullary nailing in 2-, 3- and 4-part fractures. *Injury*. 2016;47(7):S14–S19.
80. Gradl G, Dietze A, Kääh M, et al. Is locking nailing of humeral head fractures superior to locking plate fixation? *Clin Orthop Relat Res*. 2009;467(11):2986–93.
81. Boudard G, Pomares G, Milin L, et al. Locking plate fixation versus antegrade nailing of 3- and 4-part proximal humerus fractures in patients without osteoporosis Comparative retrospective study of 63 cases. *Orthop Traumatol Surg Res*. 2014;100(8):917–24.
82. Konrad G, Audigé L, Lambert S, et al. Similar outcomes for nail versus plate fixation of three-part proximal humeral fractures. *Clin Orthop Relat Res*. 2012;470(2):602–9.
83. Lekic N, Montero NM, Takemoto RC, et al. Treatment of two-part proximal humerus fractures: intramedullary nail compared to locked plating. *HSS J*. 2012;8(2):86–91.
84. Lopiz Y, Garcia-Coiradas J, Garcia-Fernandez C, et al. Proximal humerus nailing: a randomized clinical trial between curvilinear and straight nails. *J Shoulder Elbow Surg*. 2014;23(3):369–76.
85. Wang G, Mao Z, Zhang L, et al. Meta-analysis of locking plate versus intramedullary nail for treatment of proximal humeral fractures. *J Orthop Surg Res*. 2015;10:122.
86. Gupta AK, Harris JD, Erickson BJ, et al. Surgical management of complex proximal humerus fractures—a systematic review of 92 studies including 4500 patients. *J Orthop Trauma*. 2015;29:54–9. <https://doi.org/10.1097/BOT.0000000000000229>.
87. Olerud P, Ahrengart L, Ponzer S, et al. Hemiarthroplasty versus nonoperative treatment of displaced 4-part proximal humeral fractures in elderly patients: a randomized controlled trial. *J Shoulder Elbow Surg*. 2011;20:1025–33. <https://doi.org/10.1016/j.jse.2011.04.016>.
88. Boons HW, Goosen JH, van Grinsven S, et al. Hemiarthroplasty for humeral four-part fractures for patients 65 years and older: a randomized controlled trial. *Clin Orthop Relat Res*. 2012;470:3483–91. <https://doi.org/10.1007/s11999-012-2531-0>.
89. Rangan A, Handoll H, Brealey S, et al. Surgical vs nonsurgical treatment of adults with displaced fractures of the proximal humerus: the PROFHER randomized clinical trial. *JAMA*. 2015;313:1037–47. <https://doi.org/10.1001/jama.2015.1629>.
90. Boileau P, Krishnan S, Tinsi L, et al. Tuberosity malposition and migration: Reasons for poor outcomes after hemiarthroplasty for displaced fractures of the proximal humerus. *J Shoulder Elbow Surg*. 2002;11:401–12.
91. Kralinger F, Schwaiger R, Wambacher M, et al. Outcome after primary hemiarthroplasty for fracture of the head of the humerus. A retrospective multicentre study of 167 patients. *J Bone Joint Surg Br*. 2004;86:217–9.
92. Robinson C, Page R, Hill R, et al. Primary hemiarthroplasty for treatment of proximal humeral fractures. *J Bone Joint Surg Am*. 2003;85-A:1215–23.
93. Nijs S, Broos P. Outcome of shoulder hemiarthroplasty in acute proximal humeral fractures: a frustrating meta-analysis experience. *Acta Orthop Belg*. 2009;75:445–51.
94. Kontakis G, Koutras C, Tosounidis T, Giannoudis P. Early management of proximal humeral fractures with hemiarthroplasty: a systematic review. *J Bone Joint Surg Br*. 2008;90:1407–13.
95. Borowsky KA, Prasad VR, Wear LJ, et al. Is failure of tuberosity suture repair in hemiarthroplasty for fracture mechanical? *J Shoulder Elbow Surg*. 2013;22:971–8. <https://doi.org/10.1016/j.jse.2012.09.002>.
96. Lambert SM. Ischaemia, healing and outcomes in proximal humeral fractures. *EFORT Open Rev*. 2018;3:304–15. <https://doi.org/10.1302/2058-5241.3.180005>.
97. Werner BS, Daggett M, Carrillon Y, Walch G. Evaluation of lengthening in reverse shoulder arthroplasty comparing X-rays and computerised tomography. *Int Orthop*. 2015;39:2389–94. <https://doi.org/10.1007/s00264-015-2780-0>.
98. Bonneville N, Tournier C, Clavert P, et al. Hemiarthroplasty versus reverse shoulder arthroplasty in 4-part displaced fractures of the proximal humerus: multicenter retrospective study. *Orthop Traumatol Surg Res*. 2016;102(5):569–73. <https://doi.org/10.1016/j.otsr.2016.02.014>.

99. Solomon JA, Joseph SM, Shishani Y, et al. Cost analysis of hemiarthroplasty versus reverse shoulder arthroplasty for fractures. *Orthopedics*. 2016;39(4):230–4. <https://doi.org/10.3928/01477447-20160610-03>.
100. Baudi P, Campochiaro G, Serafini F, et al. Hemiarthroplasty versus reverse shoulder arthroplasty: comparative study of functional and radiological outcomes in the treatment of acute proximal humerus fracture. *Musculoskelet Surg*. 2014;98:19–25. <https://doi.org/10.1007/s12306-014-0322-3>.
101. Chalmers PN, Slikker W III, Mall NA, et al. Reverse total shoulder arthroplasty for acute proximal humeral fracture: comparison to open reduction–internal fixation and hemiarthroplasty. *J Shoulder Elbow Surg*. 2014;23:197–204. <https://doi.org/10.1016/j.jse.2013.07.044>.
102. Garrigues GE, Johnston PS, Pepe MD, et al. Hemiarthroplasty versus reverse total shoulder arthroplasty for acute proximal humerus fractures in elderly patients. *Orthopedics*. 2012;35:e703–e708708. <https://doi.org/10.3928/01477447-20120426-25>.
103. Young SW, Segal BS, Turner PC, Poon PC. Comparison of functional outcomes of reverse shoulder arthroplasty versus hemiarthroplasty in the primary treatment of acute proximal humerus fracture. *ANZ J Surg*. 2010;80:789–93. <https://doi.org/10.1111/j.1445-2197.2010.05342.x>.
104. Gallinet D, Clappaz P, Garbuio P, et al. Three or four parts complex proximal humerus fractures: hemiarthroplasty versus reverse prosthesis: a comparative study of 40 cases. *Orthop Traumatol Surg Res*. 2009;95:48–55. <https://doi.org/10.1016/j.otsr.2008.09.002>.
105. Cuff DJ, Pupello DR. Comparison of hemiarthroplasty and reverse shoulder arthroplasty for the treatment of proximal humeral fractures in elderly patients. *J Bone Joint Surg Am*. 2013;95:2050–5. <https://doi.org/10.2106/JBJS.L.01637>.
106. Sebastiá-Forcada E, Cebrián-Gómez R, Lizaar-Utrilla A, Gil-Guillén V. Reverse shoulder arthroplasty versus hemiarthroplasty for acute proximal humeral fractures. A blinded, randomized, controlled, prospective study. *J Shoulder Elbow Surg*. 2014;23:1419–26. <https://doi.org/10.1016/j.jse.2014.06.035>.
107. Boyle MJ, Youn S-M, Frampton CMA, Ball CM. Functional outcomes of reverse shoulder arthroplasty compared with hemiarthroplasty for acute proximal humeral fractures. *J Shoulder Elbow Surg*. 2013;22:32–7. <https://doi.org/10.1016/j.jse.2012.03.006>.
108. Brorson S, Salomonsson B, Jensen SL, et al. Revision after shoulder replacement for acute fracture of the proximal humerus. *Acta Orthop*. 2017;88:446–50. <https://doi.org/10.1080/17453674.2017.1307032>.